

Lernaea cyprinacea Linnaeus, 1758 (Copepoda: Lernaeidae) infection on *Betta rubra* Perugia, 1893 (Anabantiformes: Osphronemidae) from Aceh Province, Indonesia

Infecção por *Lernaea cyprinacea* Linnaeus, 1758 (Copepoda: Lernaeidae) em *Betta rubra* Perugia, 1893 (Anabantiformes: Osphronemidae) provenientes da província de Aceh, Indonésia

Firman Muhammad Nur¹; Agung Setia Batubara²; Nur Fadli³; Syamsul Rizal^{1,3}; Mohd Nor Siti-Azizah⁴; Martin Wilkes⁵; Zainal Abidin Muchlisin^{1,6*} 

¹Graduate School of Mathematics and Applied Sciences, Universitas Syiah Kuala, Banda Aceh, Indonesia

²Faculty of Mathematics and Natural Sciences, Universitas Negeri Medan, Medan, North Sumatera, Indonesia

³Faculty of Marine and Fisheries, Universitas Syiah Kuala, Banda Aceh, Indonesia

⁴Institute of Marine Biotechnology, Universiti Malaysia Terengganu, Kuala Terengganu, Malaysia

⁵Center for Agroecology, Water and Resilience, Coventry University, Coventry, United Kingdom

⁶Department of Aquaculture, Faculty of Marine and Fisheries, Universitas Syiah Kuala, Banda Aceh, Indonesia

How to cite: Nur FM, Batubara AS, Fadli N, Rizal S, Siti-Azizah MN, Wilkes M, et al. *Lernaea cyprinacea* Linnaeus, 1758 (Copepoda: Lernaeidae) infection on *Betta rubra* Perugia, 1893 (Anabantiformes: Osphronemidae) from Aceh Province, Indonesia. *Braz J Vet Parasitol* 2022; 31(1): e020421. <https://doi.org/10.1590/S1984-29612022015>

Abstract

Betta rubra is an ornamental freshwater fish endemic to northern Sumatra, Indonesia. The *B. rubra* population has decreased in recent decades, and is classified as an endangered species in the IUCN Red List. This study aims to report for the first time infection by *L. cyprinacea* in *B. rubra* harvested from the Aceh Besar region of Indonesia. The fish samples were obtained from the Cot Bira tributaries, Aceh Besar District, Indonesia from January to December 2020. The results showed that the parasite infected 6 out of 499 samples in August and September, with a prevalence and intensity rate of 1% and 2 parasites/fish, respectively. The eyes and pectoral fins were the common infection sites. Despite *B. rubra* is not an optimal host (small size) for the parasite, this parasite might serve as additional threatening factors for the endangered *B. rubra* fish population.

Keywords: Cot Bira, endangered species, endemic species, ornamental fish, parasite, population.

Resumo

Betta rubra é um peixe de água doce ornamental endêmico da região norte Sumatra, Indonésia. A população de *Betta rubra* diminuiu ao longo dos anos, sendo classificada como espécie em extinção na Lista Vermelha da IUCN. Este estudo tem como objetivo relatar pela primeira vez infecção por *L. cyprinacea* em *B. rubra* coletados na região de Aceh Besar na Indonésia. As amostras de peixes foram obtidas nos afluentes Cot Bira, distrito de Aceh Besar, Indonésia de janeiro a dezembro de 2020. Os resultados mostraram que o parasito infectou 6 das 499 amostras em agosto e setembro, com uma prevalência e taxa de intensidade de 1% e 2 parasitas/peixes, respectivamente. Os olhos e as nadadeiras peitorais foram os sítios de infecção mais comuns. Apesar de *B. rubra* não ser um hospedeiro ideal (pequeno tamanho) para o parasita, este parasita pode servir como fator de ameaça adicional para a população de peixes *B. rubra*, ameaçada de extinção.

Palavras-chave: Cot Bira, espécies ameaçadas, espécies endêmicas, peixes ornamentais, parasita, população.

Received December 3, 2021. Accepted February 17, 2022.

*Corresponding author: Zainal Abidin Muchlisin. E-mail: muchlisinza@unsyiah.ac.id



This is an Open Access article distributed under the terms of the Creative Commons Attribution License, which permits unrestricted use, distribution, and reproduction in any medium, provided the original work is properly cited.

Introduction

Betta rubra is a fish species within the family Osphronemidae. Etymologically, the “rubra” is Latin referring to “ruber” which means red, describing the bright red color pattern on the fish's body. Furthermore, *B. rubra* is a popular ornamental freshwater fish, endemic to northern Sumatra, comprising Aceh to Sibolga (Fahmi et al., 2020; Nur et al., 2020; Nur et al., 2022b), which has been classified as an endangered fish species in the IUCN Red List (Low, 2019). The fish's wild population is decreasing and becoming rare to find in nature, due to habitat perturbation (Muchlisin, 2008), low recruitment (Batubara et al., 2020), and high parasite loadings. Generally, parasites are present in the environment and the body of fishes, hence can cause infection when there is an imbalance in the host-parasite relationship (Martins et al., 2002). Parasite development is influenced by several factors, including climate change (Aleuy & Kutz, 2020), temperature increase (Cereja et al., 2018; Hossain et al., 2013; Piasecki et al., 2004), organic enrichment (Muchlisin et al., 2014; Welicky et al., 2017; Yen Le et al., 2014), acidification and dissolved oxygen (Dalu et al., 2012; Sánchez-Hernández, 2017). Parasites can become problematic in fish hosts with compromised immunity specially in artificial environments (e.g. fish farms), affecting fish health, growth, reproduction, and survival (Lieke et al., 2020; Opiyo et al., 2018; Segar et al., 2018).

Lernaea cyprinacea Linnaeus, 1758, known as anchor worm, is a common parasite of freshwater and marine fishes. It is a cosmopolitan ectoparasite belonging to the copepod group, and does not have a specific host (McAllister et al., 2011; Piasecki et al., 2004). Generally, *L. cyprinacea* embeds its anchor into the hosts' body to suck blood. In fish, the parasites usually penetrate the skin, fins, and eyes. This parasite was first reported from the Eurasian region, and it spread globally through fish introduced into various countries (Hassan et al., 2008; Tidd, 1934; Walter & Boxshall, 2021).

Infections by *L. cyprinacea* can cause pathogenesis and mortality due to bleeding from the infected organs (Carnevia & Speranza, 2003; Silva-Souza et al., 2000), leading to secondary infections caused by bacteria and fungi (Abbas et al., 2014; Boxshall & Defaye, 2008; Fast, 2014). Although the parasite is not common in temperate areas (Ahnelt et al., 2018; Bednarska et al., 2009; Piasecki et al., 2004), recent reports suggest that its distribution now includes temperate lakes in Europe (Ahnelt et al., 2018). The expansion of its geographic distribution may be related to climate change and intensity of introduced species (Muchlisin, 2008; Waicheim et al., 2019).

Lernaea cyprinacea has infected several species of freshwater and marine fish in various countries, including South Africa (Chakona et al., 2019; Welicky et al., 2017), Argentina (Plaul et al., 2010; Salinas et al., 2016), Asia (Innal & Avenant-Oldewage, 2012), Spain (Sánchez-Hernández, 2017), Siberia (Schäperclaus et al., 1991), Europe (Ahnelt et al., 2018; Stavrescu-Bedivan et al., 2011), Jepang (Nagasawa et al., 2007), Brazil (Narciso et al., 2019; Santos et al., 2020) and Israel (Lahav & Sarig, 1964). Infection occurs in capture and ornamental fisheries, and affects both farmed and wild populations (Mancini et al., 2008). This ectoparasite infects fishes of various sizes and ages (Barson et al., 2008; Gutiérrez-Galindo & Lacasa-Millán, 2005). In Indonesia, infection has been reported in goldfish *Carassius auratus* (Kriswijayanti, 2014), Arowana *Scleropages jardinii* (Shatrie et al., 2011), Gourami *Osphronemus gourami* (Kismiyati & Wulan Sari, 2014), Koi *Cyprinus rubrofusculus* (Wardany & Kurniawan, 2014), Gobi *Sicyopus zosterophorum* (Adriany et al., 2020), *Lentipes mekonggaensis* (Adriany et al., 2020), common carp *Cyprinus carpio* (Sarimudin et al., 2016; Winaruddin & Eliawardani, 2007), Tilapia *Oreochromis niloticus* (Ulkhay et al., 2018), and catfish (Fautama, 2018; Salsabilla, 2021; Ulkhay et al., 2018). Generally, these fish are infested in aquaculture systems. However, there has been no report of the infection in wild fish, especially ornamental fish in Aceh. Therefore, this study aims to report for the first time infection by *L. cyprinacea* in *B. rubra* harvested from Aceh, Indonesia.

Materials and Methods

Host sampling

The survey was conducted in Cot Bira tributaries (GPS coordinate, 05° 29.895' and 095° 27.939') Aceh Besar District, Aceh province, Indonesia, (Figure 1), from January to December 2020. Hand-nets were used to obtain the fish samples at one-week intervals for 12 months, and sampling was done from 08.00 AM to 6.00 PM. The samples were kept in live condition in a 100 mL plastic bag filled with water and oxygen. Each bag was then stocked with 1 fish to avoid cross-infection, then kept in an icebox at 24-26 °C. The samples were transported to the Laboratory of Ichthyology, Faculty of Marine and Fisheries, Syiah Kuala University, Banda Aceh for further analysis. Taxonomic identification was based on Kottelat et al. (1993). Samples were euthanized by immersing the fish in cold water

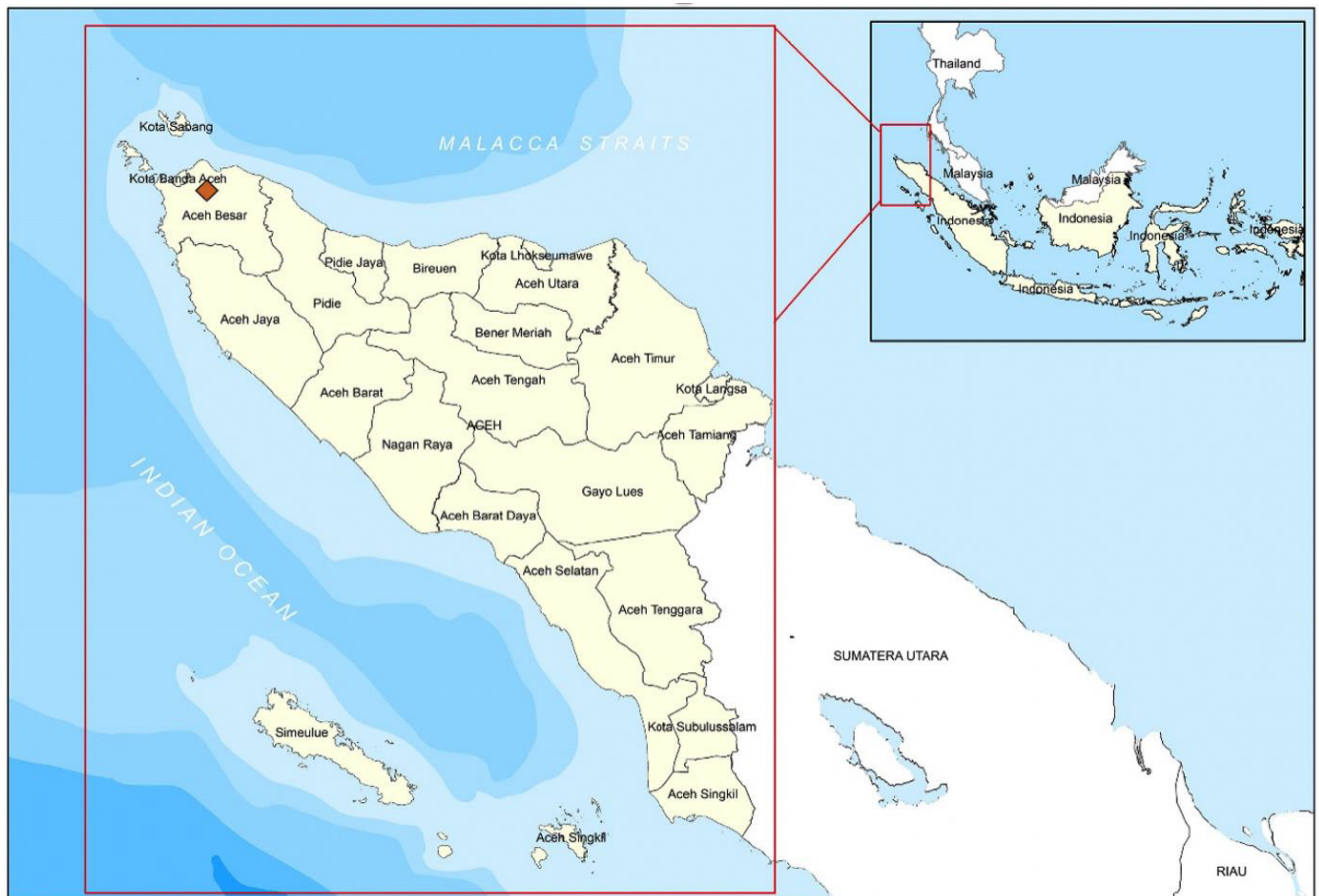

Figure 1. The map of Aceh province showed the sampling location (highlighted in red box). Indonesia map insert.

(4 °C) for 5 min, then preserved in 10% formalin (Nur et al., 2022a). These procedures were conducted in compliance with Research Ethics Guideline of Universitas Syiah Kuala No. 958/2015.

Parasite observation procedure and data analysis

A total of 499 fish samples were collected, and measured for total length (mm) and body weight (g). Subsequently, the external body of the samples was examined, including the head section, left and right sides of the body, fins, operculum, and nose using a Stereo Microscope (Euromax Stereoblue, Type SB. 1902, Made in the Netherlands). Tweezers were used to collect the parasites, which were preserved in 70% ethanol. The parasites were identified based on Avenant-Oldewage & Robinson (1996), and photographed for documentation. Prevalence and intensity of infection were calculated according to Bush et al. (1997).

Results

Prevalence and intensity

A total of 6 samples (1%) exhibited *L. cyprinacea* infection. The infected fish were discovered in August and September, with the highest prevalence of 10% occurring in August. Table 1 showed that the average intensity was 2 parasites/fish. Figure 2 illustrates that the parasite infected the eyes, skin, pectoral, dorsal, and ventral fins. The highest prevalence was observed in four organs, namely the eyes (2 out of 499), pectoral (2 out of 499), dorsal (2 out of 499), ventral fins (2 out of 499) and skin (1 out of 499), while the highest intensity was found in the eyes and pectoral fins (1.5). The ectoparasites found in *B. rubra* were identified as *L. cyprinacea* (Figure 3) based on the presence of the following characteristics, according to Avenant-Oldewage & Robinson (1996): transparent to

Table 1. Prevalence and intensity infection of the anchor worm *Lernaea cyprinacea* according to sampling time.

Parameter	Jan	Feb	Mar	Apr	May	June	July	Aug	Sept	Oct	Nov	Dec	Total
Total sample (N)	22	25	50	50	50	47	37	50	50	50	50	18	499
Infected sample (Ni)	0	0	0	0	0	0	0	5	1	0	0	0	6
Total parasite (n)	-	-	-	-	-	-	-	8	2	-	-	-	10
Prevalence (%)	-	-	-	-	-	-	-	8.0	2.1	-	-	-	1.0
Intensity (Tot.parasite/fish)	-	-	-	-	-	-	-	2.0	2.0	-	-	-	2.0



Figure 2. *Betta rubra* specimen infected by the anchor worm, *Lernaea cyprinacea*. The parasite is highlighted in the red circle.

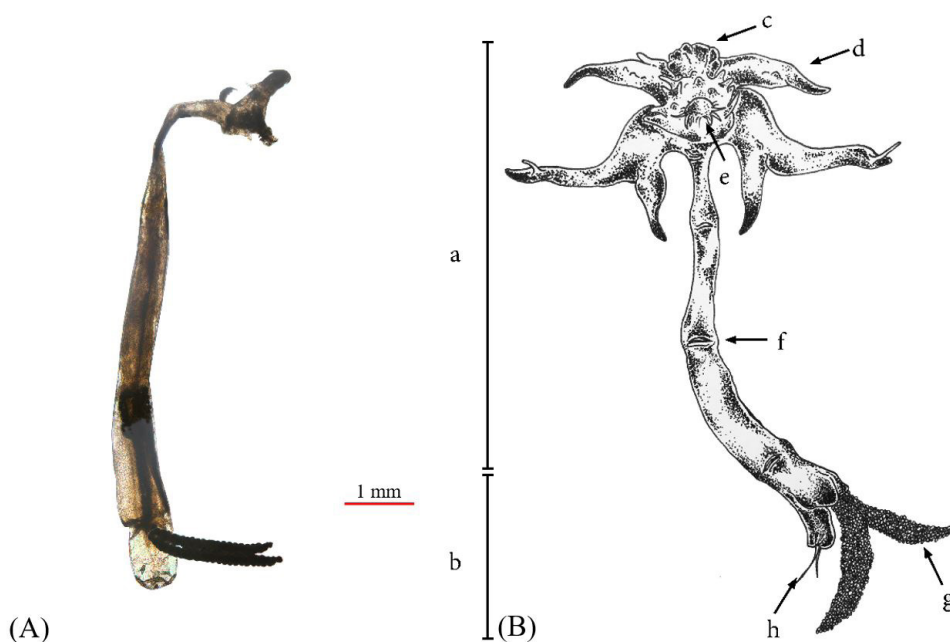


Figure 3. (A) The female anchor worm *Lernaea cyprinacea*. (B) The illustration of the female *L. cyprinacea* describes the body part of the: (a) anterior part, (b) posterior part, (c) antenna, (d) anchor, (e) the ventral anchor, (f) maxillary, (g) egg yolk sac, and (h) uropod.

brownish-yellow body color, length ranging from 9.79 to 10.93 mm, antennas (c), maxillary, and an anterior holdfast (a), which consists of two pairs of anchors with an average length of 1.23 ± 0.07 mm (d), posterior end provided with egg sacs and uropods (b)

Habitat description

The tributary of the Bira Cot has a depth ranging from 14 to 45 cm, and a river width of 0.5 to 1.5 m with a slow current. The in situ measurements of the water quality parameters showed that the temperature, pH, and dissolved oxygen ranged from 24.3- 28.8 °C, 7.22 - 8.56, and 7.8-8.8 ppm, respectively (Table 2).

Table 2. Water temperature, pH and dissolved oxygen at the Cot Bira Tributaries.

Parameter	Month												Range
	Jan	Feb	Mar	Apr	May	June	July	Aug	Sep	Oct	Nov	Dec	
pH	8.27±0.1	8.17±0.1	8.18±0.1	7.77±0.2	7.64±0.2	7.81±0.1	7.80	7.51±0.3	7.65±0.4	7.43±0.1	8.16±0.2	8.37±0.1	7.22-8.56
Temperature (°C)	26±0.8	0.4	27.6±1.4	26.2±0.4	25.9±0.5	26.7±0.3	25.2±0.9	26.2±0.7	27.1±0.6	27.5±0.7	28.1±1.0	28.0±0.6	24.3-28.8
Dissolved oxygen (mg L ⁻¹)	8.2±0.1	8.1±0.2	8.6±0.2	8.6±0.2	8.5±0.1	8.2±0.2	8.4±0.1	8.3±0.1	8.1±0.2	8.2±0.2	7.9±0.1	8.2±0.1	7.8-8.8

Discussion

This study showed that the prevalence and intensity of *L. cyprinacea* on *Betta rubra* was low, and the infection was observed in August and September. This is probably due to water temperature variation, which was at 26-27 °C during times when peak infection rates occurred, slightly higher than other months. According to Piasecki et al. (2004), the optimal temperature for *L. cyprinacea* development ranges from 25 to 28 °C (Hossain et al., 2018; Plaul et al., 2010). According to Kupferberg et al. (2009), water temperatures above 20 °C increase *L. cyprinacea* infection. On the other hand, it has been demonstrated that lower temperature can decrease the prevalence and intensity of infections by this parasite (Plaul et al., 2010).

In the present study, the eyes and pectoral fins of *B. rubra* were the sites most infected by *L. cyprinacea*, followed by the skin, dorsal, and ventral fins. Several studies showed that this parasite commonly infects the gills, mouth, and nostrils (Abbas et al., 2014; Acosta et al., 2013; Gutiérrez-Galindo & Lacasa-Millán, 2005). Infections by *L. cyprinacea* in the cornea or tissues around the eye of fishes can lead to fibrosis and bleeding (Eagle, 2012), as well as vision impairment and blindness (Padrós et al., 2018; Shariff, 1985; Uzman & Rayner, 1958), making the host more susceptible to predation (Ubels et al., 2018). The fact that the eyes are a common infection site could be due to the cornea having many blood vessels and a thin membrane, being easier for the parasite to penetrate.

Lernaea cyprinacea can damage the scales of fishes by penetrating the skin into the muscles (Bozorgnia et al., 2018), hence infection of fish larvae will cause imminent death (Innal et al., 2017). Infected fish typically become malnourished following infection (Salinas et al., 2019; Sayyadzadeh & Joladeh-Roudbar, 2014; Smit et al., 2017). Furthermore, parasites deeply attached and embedded in the fish's body are difficult to release (Furtado et al., 2019). According to Mirzaei (2015), *L. cyprinacea* infection forms a wound that is easily infected by opportunistic bacteria, such as *Aeromonas hydrophila* (Hossain et al., 2013; Mancini et al., 2006). Also, infection of the gills causes epithelial proliferation and increases the spread of bacterial infection (Faruk, 2018; Gjessing et al., 2019; Shariff et al., 1986).

The observed prevalence and intensity of *L. cyprinacea* infection in *B. rubra* were relatively low in this study. This is in line with a study on *B. splendens* in Brazil, where the occurrence was due to the small size of the benthic fish (Santos et al., 2020). Ahnelt et al. (2018) obtained similar results in *Knipowitschia panizzae* and *Pomatoschistus canestrinii*, where the small benthic fishes had a short life cycle of one year and low infection rate. Nagasawa et al. (2007) also reported low infection rates in the barbell steed (*Hemibarbus labeo*), dark chub (*Zacco temminckii*), and the small Amur catfish (*Silurus asotus*). This was related to the short life cycle and small body surface area of these species, which limits the attachment of the parasite (Hua et al., 2019; Raibaut et al., 1998). In the present study, the size of the fish host *B. rubra* ranged from 28.82-37.17 mm.

According to Tokşen et al. (2014), *L. cyprinacea* is commonly found in aquatic habitats with low water velocity and warm water temperatures, as observed in this study. The field observations showed that *B. rubra* habitat in Aceh

Besar was damaged due to industrialization and channel engineering, causing topographic changes and silting of tributaries. This results in reduced depth and flow, increasing the temperature and possibly facilitating this ectoparasite's infection routes and reproduction. Therefore, it is necessary to address degradation in the tributaries and restore the *B. rubra* habitat to reduce the chances of infections by *L. cyprinacea*.

Conclusion

This study is the first record of *L. cyprinacea* in a natural population of *B. rubra* from Indonesia. The parasitic prevalence was categorized as occasional (1%) with a low intensity level of 2 parasites/fish, occurring in August and September. The eyes and pectoral fins were the most commonly infected sites on hosts.

Acknowledgements

This study was supported by the Universitas Syiah Kuala through Riset Unggulan Unsyiah Percepatan Doktor (PRUUPD) 2021 (Contract Number: 332/UN11/SPK/PNBP/2021). Therefore, the authors are grateful to the Rector of the Universitas Syiah Kuala for their support.

References

- Abbas F, Ashraf M, Hafeez-ur-Rehman M, Iqbal KJ, Abbas S, Javid A. *Lernaea* susceptibility, infestation and its treatment in indigenous major and exotic Chinese carps under polyculture system. *Pak J Zool* 2014; 46(5): 1215-1222.
- Acosta AA, Carvalho ED, Silva RJ. First record of *Lernaea cyprinacea* (Copepoda) in a native fish species from a Brazilian river. *Neotrop Helminthol* 2013; 7(1): 7-12.
- Adriany DT, Bakri AA, Darwis D, Anshary H, Gani A. Inventarisasi dan identifikasi parasit yang menginfeksi ikan gobi (*Sicyopus zosterophorum*) dan ikan lentipes (*Lentipes mekonggaensis*) yang didapat dari Sungai Koyoan, Luwuk Banggai, Sulawesi Tengah. *Proc Simp Nas Kel Perik* 2020; 7(1): 247-254.
- Ahnelt H, Konecny R, Gabriel A, Bauer A, Pompei L, Lorenzoni M, et al. First report of the parasitic copepod *Lernaea cyprinacea* (Copepoda: Lernaeidae) on gobioid fishes (Teleostei: Gobonellidae) in southern Europe. *Knowl Manag Aquat Ecosyst* 2018; 419(34): 1-6. <http://dx.doi.org/10.1051/kmae/2018022>.
- Aleuy OA, Kutz S. Adaptations, life-history traits and ecological mechanisms of parasites to survive extremes and environmental unpredictability in the face of climate change. *Int J Parasitol Parasites Wildl* 2020; 12: 308-317. <http://dx.doi.org/10.1016/j.ijppaw.2020.07.006>. PMID:33101908.
- Avenant-Oldewage A, Robinson J. Aspects of the morphology of the parasitic copepod *Lernaea cyprinacea* Linnaeus, 1758 and notes on its distribution in Africa. *Crustaceana* 1996; 69(5): 610-626. <http://dx.doi.org/10.1163/156854096X00628>.
- Barson M, Mulonga A, Nhwatiwa T. Investigation of a parasitic outbreak of *Lernaea cyprinacea* Linnaeus (crustacea: copepoda) in fish from Zimbabwe. *Afr Zool* 2008; 43(2): 175-183. <http://dx.doi.org/10.1080/15627020.2008.11657234>.
- Batubara AS, Nur FM, Muchlisin ZA. *Ikan air tawar endemik di Perairan Aceh, Indonesia (The endemic freshwater fish in the Aceh Province waters, Indonesia)*. Banda Aceh: Bandar Publishing; 2020.
- Bednarska M, Bednarski M, Soltysiak Z, Polechonski R. Invasion of *Lernaea cyprinacea* in rainbow trout (*Oncorhynchus mykiss*). *Acta Sci Pol Med Vet* 2009; 8(4): 27-32.
- Boxshall GA, Defaye D. Global diversity of copepods (Crustacea: Copepoda) in freshwater. *Hydrobiologia* 2008; 595(1): 195-207. <http://dx.doi.org/10.1007/s10750-007-9014-4>.
- Bozorgnia A, Sharifi N, Youssefi M. *Acipenser stellatus* as a new host record for *Lernaea cyprinacea* linnaeus, 1758 (crustacea; copepoda), a parasites of freshwater fishes in Iran. *J Aquac Mar Biol* 2018; 7(3): 123-125. <http://dx.doi.org/10.15406/jamb.2018.07.00197>.
- Bush AO, Lafferty KD, Lotz JM, Shostak AW. Parasitology meets ecology on its own terms: margolis et al. revisited. *J Parasitol* 1997; 83(4): 575-583. <http://dx.doi.org/10.2307/3284227>. PMID:9267395.
- Carnevia D, Speranza G. First report of *Lernaea cyprinacea* L., 1758 in Uruguay, introduced by goldfish *Carassius auratus* (L., 1758) and affecting axolotl *Ambystoma mexicanum* (Shaw, 1798). *Bull Eur Assoc Fish Pathol* 2003; 23(5): 255-256.
- Cereja R, Mendonça V, Dias M, Vinagre C, Gil F, Diniz M. Physiological effects of cymothoid parasitization in the fish host *Pomatoschistus microps* (Krøyer, 1838) under increasing ocean temperatures. *Ecol Indic* 2018; 95(Pt 1): 176-182. <http://dx.doi.org/10.1016/j.ecolind.2018.07.045>.

- Chakona A, Rennie C, Kadye WT. First record of *Lernaea cyprinacea* (Copepoda: Lernaeidae) on an imperilled endemic anabantid, *Sandelia bainsii* (Teleostei: Anabantidae), from the Eastern Cape province, South Africa. *Afr J Aquat Sci* 2019; 44(2): 183-187. <http://dx.doi.org/10.2989/16085914.2019.1619513>.
- Dalu T, Nhiwatiwa T, Clegg B, Barson M. Impact of *Lernaea cyprinacea* Linnaeus 1758 (Crustacea: Copepoda) almost a decade after an initial parasitic outbreak in fish of Malilangwe Reservoir, Zimbabwe. *Knowl Manag Aquat Ecosyst* 2012; 406(3): 1-9. <http://dx.doi.org/10.1051/kmae/2012020>.
- Eagle RC. *Eye pathology: an atlas and text*. Philadelphia: Lippincott Williams & Wilkins; 2012.
- Fahmi MR, Kusriani E, Hayuningtyas EP, Sinansari S, Gustiano R. DNA barcoding using coi gene sequences of wild betta fighting fish from Indonesia: phylogeny, status and diversity. *Indones Fish Res J* 2020; 26(2): 97-105. <http://dx.doi.org/10.15578/ifrj.26.2.2020.97-105>.
- Faruk MAR. *Fish parasite: infectious diseases associated with fish parasite*. Florida: CRC Press; 2018.
- Fast MD. Fish immune responses to parasitic copepod (namely sea lice) infection. *Dev Comp Immunol* 2014; 43(2): 300-312. <http://dx.doi.org/10.1016/j.dci.2013.08.019>. PMID:24001580.
- Fautama FN. *Inventarisasi ektoparasit ikan lele (Clarias Gariepinus Burchell, 1822) pada beberapa lokasi budidaya di Kabupaten Aceh Besar* [thesis]. Banda Aceh: UIN Ar-Raniry; 2018.
- Furtado WE, Cardoso L, Figueredo AB, Marchiori NC, Martins ML. Histological and hematological alterations of silver catfish *Rhamdia quelen* highly parasitized by *Lernaea cyprinacea*. *Dis Aquat Organ* 2019; 135(2): 157-168. <http://dx.doi.org/10.3354/dao03386>. PMID:31392968.
- Gjessing MC, Steinum T, Olsen AB, Lie KI, Tavoranpanich S, Colquhoun DJ, et al. Histopathological investigation of complex gill disease in sea farmed Atlantic salmon. *PLoS One* 2019; 14(10): e0222926. <http://dx.doi.org/10.1371/journal.pone.0222926>. PMID:31581255.
- Gutiérrez-Galindo JF, Lacasa-Millán MI. Population dynamics of *Lernaea cyprinacea* (Crustacea: Copepoda) on four cyprinid species. *Dis Aquat Organ* 2005; 67(1-2): 111-114. <http://dx.doi.org/10.3354/dao067111>. PMID:16385816.
- Hassan M, Beatty SJ, Morgan DL, Doupe RG, Lymbery AJ. An introduced parasite, *Lernaea cyprinacea* L., found on native freshwater fishes in the south west of Western Australia. *J R Soc West Aust* 2008; 91(2): 149-153.
- Hossain MMM, Ferdoushi J, Rupom A. Biology of anchor worms (*Lernaea cyprinacea*). *J Entomol Zool Stud* 2018; 6(1): 910-917. <http://dx.doi.org/10.22271/j.ento.2018.v6.i1.m.3047>.
- Hossain MMM, Rahman MZ, Islam MA, Alam ME, Rahman H. *Lernaea* (anchor worm) investigations in fish. *Int J Anim Fish Sci* 2013; 1(1): 12-19.
- Hua CJ, Zhang D, Zou H, Li M, Jakovlić I, Wu SG, et al. Morphology is not a reliable taxonomic tool for the genus *Lernaea*: molecular data and experimental infection reveal that *L. cyprinacea* and *L. cruciata* are conspecific. *Parasit Vectors* 2019; 12(1): 579. <http://dx.doi.org/10.1186/s13071-019-3831-y>. PMID:31829242.
- Innal D, Avenant-Oldewage A, Dogangil B, Stavrescu-Bedivan MM, Ozmen O, Mavruk S. Susceptibility of endemic and non-indigenous fish to *Lernaea cyprinacea* (Copepoda: Lernaeidae): a case study from Düger Spring Creek (Burdur-Turkey). *Bull Eur Assoc Fish Pathol* 2017; 37(3): 100-109.
- Innal D, Avenant-Oldewage A. Occurrence of *Lernaea cyprinacea* on mosquito fish (*Gambusia affinis*) from Kundu Estuary (Antalya-Turkey). *Bull Eur Assoc Fish Pathol* 2012; 32(4): 140-147.
- Kismiyati K, Wulan Sari PD. Variasi morfologi holdfast *Lernaea* yang menyerang ikan Gurami di Jawa Timur. *JIPK* 2014; 6(1): 67-70. <http://dx.doi.org/10.20473/jipk.v6i1.11390>.
- Kottelat M, Whitten A, Katikasari S, Wirjoatmodjo S. *Ikan air tawar Indonesia bagian Barat dan Sulawesi*. Jakarta: Periplus Edition; 1993.
- Kriswijayanti BD. *Identifikasi dan derajat infestasi Lernaea pada ikan Maskoki (Carassius auratus) di Kabupaten Tulungagung, Jawa Timur* [thesis]. Surabaya: Universitas Airlangga; 2014.
- Kupferberg SJ, Catenazzi A, Lunde K, Lind AJ, Palen WJ. Parasitic copepod (*Lernaea cyprinacea*) outbreaks in foothill yellow-legged frogs (*Rana boylei*) linked to unusually warm summers and amphibian malformations in Northern California. *Copeia* 2009; 3(3): 529-537. <http://dx.doi.org/10.1643/CH-08-011>.
- Lahav M, Sarig S. Observation on the biology of *Lernaea cyprinacea* L. in fish ponds in Israel. *Bamidgeh* 1964; 16(3): 77-86.
- Lieke T, Meinelt T, Hoseinifar SH, Pan B, Straus DL, Steinberg CEW. Sustainable aquaculture requires environmental-friendly treatment strategies for fish diseases. *Rev Aquacult* 2020; 12(2): 943-965. <http://dx.doi.org/10.1111/raq.12365>.

- Low BW. *Betta rubra*. The IUCN Red List of Threatened Species; 2019. <http://dx.doi.org/10.2305/IUCN.UK.2019-2.RLTS.T91310582A91310586.en>.
- Mancini M, Bucco C, Salinas V, Larriestra A, Tanzola R, Guagliardo S. Seasonal variation of parasitism in pejerrey *Odontesthes bonariensis* (Atheriniformes, Atherinopsidae) from La Viña reservoir (Córdoba, Argentina). *Rev Bras Parasitol Vet* 2008; 17(1): 28-32. <http://dx.doi.org/10.1590/S1984-29612008000100006>. PMID:18554437.
- Mancini M, Rodriguez C, Prosperi C, Salinas V, Bucco C. Main diseases of pejerrey (*Odontesthes bonariensis*) in central Argentina. *Pesq Vet Bras* 2006; 26(4): 205-210. <http://dx.doi.org/10.1590/S0100-736X2006000400004>.
- Martins ML, Onaka EM, Moraes FR, Bozzo FR, Paiva AMFC, Gonçalves A. Recent studies on parasitic infections of freshwater cultivated fish in the state of São Paulo, Brazil. *Acta Scientiarum* 2002; 24(4): 981-985.
- McAllister CT, Burse CR, Martin SD. *Lernaea cyprinacea* (Crustacea: Copepoda: Lernaeidae) anchor worms from two larval aquatic insects (Ephemeroptera: Baetidae: Trichoptera: Hydropsychidae) in northeastern Oklahoma. *Proc Okla Acad Sci* 2011; 91: 37-40.
- Mirzaei M. Prevalence and histopathologic study of *Lernaea cyprinacea* in two species of ornamental fish (*Poecilia latipinna* and *Xiphophorus helleri*) in Kerman, south-east Iran. *Turkiye Parazit Derg* 2015; 39(3): 222-226. <http://dx.doi.org/10.5152/tpd.2015.3960>. PMID:26470930.
- Muchlisin ZA, Munazir AM, Fuady Z, Winaruddin W, Sugianto S, Adlim M, et al. Prevalence of ectoparasites on mahseer fish (*Tor tambra* Valenciennes, 1842) from aquaculture ponds and wild population of Nagan Raya District, Indonesia. *HVM Bioflux* 2014; 6(3): 148-152.
- Muchlisin ZA. Ikan depik yang terancam punah. *Bul Leus* 2008; 6(17): 9-12.
- Nagasawa K, Inoue A, Myat S, Umino T. New host records for *Lernaea cyprinacea* (Copepoda), a parasite of freshwater fishes, with a checklist of the Lernaeidae in Japan (1915-2007). *J Grad Sch Biosp Sci* 2007; 4621-33.
- Narciso RB, Acosta AA, Nobile AB, de Lima FP, Freitas-Souza D, da Silva RJ. *Lernaea cyprinacea* (Copepoda: Lernaeidae) in *Piabarchus stramineus* (characiformes: characidae) from the Taquari River, São Paulo State, Brazil. *Biologia* 2019; 74(9): 1171-1179. <http://dx.doi.org/10.2478/s11756-019-00240-z>.
- Nur FM, Batubara AS, Eriani K, Tang UM, Muhammadar AA, Siti-Azizah MN, et al. Effect of water temperature on the physiological responses in *Betta rubra*, Perugia 1893 (Pisces: osphronemidae). *Int Aquatic Research* 2020; 12(3): 209-218. <http://dx.doi.org/10.22034/iar.2020.1900150.1053>.
- Nur FM, Batubara AS, Fadli N, Rizal S, Siti-Azizah MN, Muchlisin ZA. Diversity, distribution, and conservation status of Betta fish (Teleostei: Osphronemidae) in Aceh Waters, Indonesia. *Eur Zool J* 2022a; 89(1): 135-144. <http://dx.doi.org/10.1080/24750263.2022.2029587>.
- Nur FM, Batubara AS, Fadli N, Rizal S, Siti-Azizah MN, Muchlisin ZA. Elucidating species diversity of genus *Betta* from Aceh waters Indonesia using morphometric and genetic data. *Zool Anz* 2022b; 296: 129-140. <http://dx.doi.org/10.1016/j.jcz.2021.12.004>.
- Opiyo MA, Marijani E, Muendo P, Odede R, Leschen W, Charo-Karisa H. A review of aquaculture production and health management practices of farmed fish in Kenya. *Int J Vet Sci Med* 2018; 6(2): 141-148. <http://dx.doi.org/10.1016/j.ijvsm.2018.07.001>. PMID:30564588.
- Padrós F, Knudsen R, Blasco-Costa I. Histopathological characterisation of retinal lesions associated to *Diplostomum* species (platyhelminthes: trematoda) infection in polymorphic arctic charr *Salvelinus alpinus*. *Int J Parasitol Parasites Wildl* 2018; 7(1): 68-74. <http://dx.doi.org/10.1016/j.ijppaw.2018.01.007>. PMID:29988817.
- Piasecki W, Goodwin AE, Eiras JC, Nowak BF. Importance of copepoda in freshwater aquaculture. *Zool Stud* 2004; 43(2): 193-205.
- Plaul SE, García Romero N, Barbeito CG. Distribution of the exotic parasite, *Lernaea cyprinacea* (Copepoda, Lernaeidae) in Argentina. *Bull Eur Assoc Fish Pathol* 2010; 30(2): 65-73.
- Raubaut A, Combes C, Benoit F. Analysis of the parasitic copepod species richness among Mediterranean fish. *J Mar Syst* 1998; 15(1-4): 185-206. [http://dx.doi.org/10.1016/S0924-7963\(97\)00079-1](http://dx.doi.org/10.1016/S0924-7963(97)00079-1).
- Salinas ZA, Babini MS, Grenat PR, Biolé FG, Martino AL, Salas NE. Effect of parasitism of *Lernaea cyprinacea* on tadpoles of the invasive species *Lithobates catesbeianus*. *Heliyon* 2019; 5(6): e01834. <http://dx.doi.org/10.1016/j.heliyon.2019.e01834>. PMID:31294092.
- Salinas ZA, Biolé FG, Grenat PR, Pollo FE, Sala NE, Martino AL. First report of *Lernaea cyprinacea* (Copepoda: Lernaeidae) in tadpoles and newly-metamorphosed frogs in wild populations of *Lithobates catesbeianus* (Anura: Ranidae) in Argentina. *J Herpetol* 2016; 15(1): 43-50. <http://dx.doi.org/10.11606/issn.2316-9079.v15i1p43-50>.
- Salsabilla A. *Prevalensi dan intensitas ektoparasit pada kolam budidaya ikan lele (Clarias batrachus) Tradisional dan bioflok di kawasan Aceh Besar* [thesis]. Banda Aceh: Universitas Syiah Kuala; 2021.
- Sánchez-Hernández J. *Lernaea cyprinacea* (Crustacea: Copepoda) in the Iberian Peninsula: climate implications on host-parasite interactions. *Knowl Manag Aquat Ecosyst* 2017; 418(11): 1-8. <http://dx.doi.org/10.1051/kmae/2017002>.

- Santos EL, Silva TJ, Lima MR, Junior RFTC, da Silva SJC, Soares EC. First record of *Lernaea cyprinacea* (Linnaeus, 1758) (Copepoda: Cyclopoida) on *Betta splendens* in Brazil. *Rev Principia* 2020; 50155-167. <http://dx.doi.org/10.18265/1517-03062015v1n50p155-167>.
- Sarimudin R, Nur I, Idris M. Pengaruh aktivitas transportasi terhadap serangan parasit pada ikan mas (*Cyprinus carpio*). *J Med Akua* 2016; 1(1): 1-14. <http://dx.doi.org/10.33772/jma.v1i1.4267>.
- Sayyadzadeh G, Joladeh Roudbar A. Occurrence of *Lernaea cyprinacea* (Crustacea: Copepoda) in an endemic cyprinid fish, *Chondrostoma orientale* Bianco & Banarescu, 1982 from the Kor River Basin, southwestern Iran. *Iran J Ichthyol* 2014; 1(3): 214-217.
- Schäperclaus W, Kulow H, Schreckenbach K. *Fish diseases*. Berlin: Akademie-Verlag; 1991.
- Segar ST, Mardiatuti A, Wheeler PM, Cook JM. Detecting the elusive cost of parasites on fig seed production. *Acta Oecol* 2018; 90: 9069-9074. <http://dx.doi.org/10.1016/j.actao.2018.03.002>.
- Shariff M, Kabata Z, Sommerville C. Host susceptibility to *Lernaea cyprinacea* L. and its treatment in a large aquarium system. *J Fish Dis* 1986; 9(5): 393-401. <http://dx.doi.org/10.1111/j.1365-2761.1986.tb01032.x>.
- Shariff M. *Studies on the biology, host-parasite interactions and distribution of Lernaea spp. in West Malaysia* [thesis]. Stirling: University of Stirling; 1985.
- Shatrie DN, Imamudin K, Nurcahyo W, Triyanto T. Identifikasi *Lernaea* sp. yang menginfeksi ikan arwana irian (*Scleropages jardinii* Saville-Kent, 1892) di Merauke, Jakarta, Bogor dan Depok. *Ber Biol* 2011; 10(6): 807-817. <http://dx.doi.org/10.14203/beritabiologi.v10i6.1950>.
- Silva-Souza AT, Almeida SC, Machado PM. Effect of the infestation by *Lernaea cyprinacea* Linnaeus, 1758 (Copepoda, Lernaeidae) on the leucocytes of *Schizodon intermedius* Garavella & Britski, 1990 (Osteichthyes, Anostomidae). *Rev Bras Biol* 2000; 60(2): 217-220. <http://dx.doi.org/10.1590/S0034-71082000000200004>. PMID:10959104.
- Smit NJ, Malherbe W, Hadfield KA. Alien freshwater fish parasites from South Africa: diversity, distribution, status and the way forward. *Int J Parasitol Parasites Wildl* 2017; 6(3): 386-401. <http://dx.doi.org/10.1016/j.ijppaw.2017.06.001>. PMID:30951573.
- Stavrescu-Bedivan M-M, Popa OP, Aioanei FT, Popa LO. Infestation of the pumpkinseed *Lepomis gibbosus* (Teleostei: Cyprinidae) by the copepod *Lernaea cyprinacea* (Crustacea)-some ecological aspects. *Trav Mus Natl Hist Nat Grigore Antipa* 2011; 54(1): 63-68. <http://dx.doi.org/10.2478/v10191-011-0004-4>.
- Tidd WM. Recent Infestations of goldfish and carp by the "anchor parasite", *Lernaea Carassii*. *Trans Am Fish Soc* 1934; 64(1): 176-180. [http://dx.doi.org/10.1577/1548-8659\(1934\)64\[176:RIOGAC\]2.0.CO;2](http://dx.doi.org/10.1577/1548-8659(1934)64[176:RIOGAC]2.0.CO;2).
- Tokşen E, Zoral MA, Şirin C. Occurrence of *Lernaea* spp. infection in rainbow trout (*Oncorhynchus mykiss*) farmed in Turkey. *Bull Eur Assoc Fish Pathol* 2014; 35(1): 8-13.
- Ubels JL, DeJong RJ, Hoolsema B, Wurzberger A, Nguyen T-T, Blankespoor HD, et al. Impairment of retinal function in yellow perch (*Perca flavescens*) by *Diplostomum baeri* metacercariae. *Int J Parasitol Parasites Wildl* 2018; 7(2): 171-179. <http://dx.doi.org/10.1016/j.ijppaw.2018.05.001>. PMID:29988865.
- Ulkhag MF, Budi DS, Kismiyati K. Inventarisasi ektoparasit protozoa dan arthropoda yang menginfestasi ikan air tawar di Kota Banyuwangi, Jawa Timur. *J Aquat Sci* 2018; 3(1): 9-16.
- Uzmann JR, Rayner HJ. Record of the parasitic copepod *Lernaea cyprinacea* L. in Oregon and Washington fishes. *J Parasitol* 1958; 44(4, Section 1): 452-453. <http://dx.doi.org/10.2307/3274337>. PMID:13564365.
- Waicheim MA, Arbetman MP, Rauque C, Viozzi G. The invasive parasitic copepod *Lernaea cyprinacea*: updated host-list and distribution, molecular identification and infection rates in Patagonia. *Aquat Invasions* 2019; 14(2): 350-364. <http://dx.doi.org/10.3391/ai.2019.14.2.12>.
- Walter TC, Boxshall G. *World of Copepods Database* [online]. 2021 [cited 2021 Aug 16]. Available from: <https://www.marinespecies.org/copepoda>
- Wardany KH, Kurniawan N. Eksplorasi ektoparasit pada ikan famili cyprinidae di kolam rumah makan wilayah Malang Raya. *Biotropika* 2014; 2(2): 87-91.
- Welicky RL, De Swardt J, Gerber R, Netherlands EC, Smit NJ. Drought-associated absence of alien invasive anchorworm, *Lernaea cyprinacea* (Copepoda: Lernaeidae), is related to changes in fish health. *Int J Parasitol Parasites Wildl* 2017; 6(3): 430-438. <http://dx.doi.org/10.1016/j.ijppaw.2017.01.004>. PMID:30951570.
- Winaruddin W, Eliawardani E. The Ectoparasites Inventory on Cultured Carp in Floating Cage Net at Laut Tawar Lake Kabupaten Aceh Tengah. *J Kedokt Hewan* 2007; 1(2): 66-69.
- Yen Le TT, Rijdsdijk L, Sures B, Jan Hendriks A. Accumulation of persistent organic pollutants in parasites. *Chemosphere* 2014; 108: 145-151. <http://dx.doi.org/10.1016/j.chemosphere.2014.01.036>. PMID:24582601.